



## Seattle-King County EMS

Emergency Medical Services Division  
Public Health - Seattle/King County  
999 3<sup>rd</sup> Avenue, Suite 700  
Seattle, Washington 98104  
(206) 296-4863

January 2007

# CBT/OATEP 301 **Soft Tissue Injuries**

print version of EMS Online Course  
[www.emsonline.net](http://www.emsonline.net)

## Introduction

Soft tissue is a term that encompasses all body tissue except the bones and includes skin, muscles, vessels, ligaments, tendons, and nerves. Soft tissue injuries can range from the trivial, such as a scraped knee, to the critical that includes internal bleeding.

### Before You Begin

This is a continuing education and recertification course for EMTs. It covers fundamental EMT-Basic concepts and terminology as well as advanced material. We highly recommend completing the case studies and practice exam before completing the exam.

We also recommend that you review an EMT textbook chapter covering stroke as a refresher before taking the exam; for example: Chapter 24 in *Emergency Care and Transportation of the Sick and Injured*, 9th edition (AAOS).

### Objectives

CBT/OTEP 301 is an EMT continuing education and recertification course. After completing this course you will be able to:

1. Identify the layers of the skin.
2. Identify the types of closed and open soft tissue injuries.
3. Identify the factors to consider in assessing MOI.
4. Identify the statement that best explains kinetic energy as it relates to MOI.
5. Identify the correct technique for assessing CMS.
6. Demonstrate knowledge of assessment of soft tissue injuries including recognition of related signs and symptoms.
7. Identify the emergency medical care for a patient with a closed soft tissue injury.
8. Identify the emergency medical care for a patient with an open soft tissue injury.

## Terms You Should Already Know

**abrasion** — Damage to the superficial layer of skin as a result of rubbing or scraping across a rough or hard surface.

**avulsion** — Soft tissue that is either torn completely loose or is hanging as a flap.

**contusion** — A traumatic injury to the tissues beneath the skin without a break in the skin.

**dislocation** — An injury that occurs when the bone ends that form a joint become separated. For example, a dislocated shoulder.

**ecchymosis** — Discoloration under the skin that is caused when blood leaks out into the surrounding soft tissues causing the skin to turn different colors.

**edema** — Swelling as a result of inflammation or abnormal fluid under the skin.

**epidermis** - The outer layer of the skin that keeps you waterproof.

**hematoma** — Blood collected within the skin, muscles or in a body cavity.

**laceration** — A cut in the skin.

**subcutaneous tissue** — A layer of tissue, composed largely of fat, that lies directly under the dermis.

**sprain** — A joint injury involving damage to supporting ligaments and partial or temporary dislocation of bone ends.

**strain** — Stretching or tearing of a muscle; also called a muscle pull.

## New Terms

**body substance isolation (BSI)** – An infection control concept and practice that assumes all body fluids are potentially infectious. This includes the use of gloves and eye protection and can include gowns and masks.

**compartment syndrome** — An elevation of pressure within the compartment that contains muscles, nerves and vessels. Symptoms include skin that is very sensitive to touch or pressure, pain on stretching of affected muscles and decreased strength. It usually develops several hours after an injury.

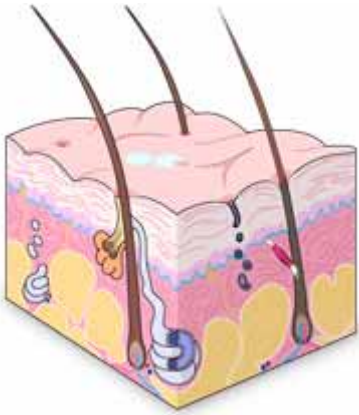
**fascia** — A band of tough fibrous connective tissue. It lies deep under the skin and forms an outer layer for the muscles. Think of it as the sack that holds the muscle fibers.

## Anatomy

The skin is the largest organ in the body. It protects against heat, light, injury and infection. It also regulates body temperature; provides sensory input for heat, touch and pain; and stores water, fat and vitamin D.

The skin has three layers:

- epidermis
- dermis
- subcutaneous layer



### Layers of the Skin

The **epidermis** is the thin outer layer of the skin. This layer contains cells that continually divide, forming new cells and replacing the old ones that are shed from the surface of the skin.

The **dermis** is the layer below the epidermis. It contains:

- blood vessels
- lymph vessels
- hair follicles
- sweat glands

The dermis is held together by a protein called collagen that gives the skin its strength and resilience. This layer also contains pain and touch receptors.

The **subcutaneous layer** is the inner layer of the skin and is made up of a network of collagen and fat cells. It helps conserve body heat and protect internal organs from injury by acting as a shock absorber.

## Closed Injuries

A closed soft tissue injury is an injury to the tissues beneath the skin where the skin or mucous membrane remains intact. The extent of damage may not be readily visible. Swelling, bruising, immobility and pain at the injury site may indicate a closed injury. You will often find closed injuries in accidents where a significant mechanism of injury was involved.

When assessing trauma, you should always suspect injury to soft tissues and organs beneath the area of impact or observable surface injuries. For example, a baseball bat to the abdomen may cause a bruise over the umbilicus, but this mechanism might also damage the underlying organs such as the stomach, bowel, pancreas, spleen and liver.

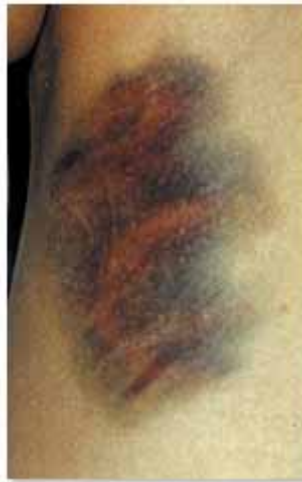## Edema

Injury to soft tissues from blunt force leads to swelling and edema. **Edema** is the medical term for swelling as a result of fluid in the skin or muscle. If the swelling becomes great enough it may put pressure on blood vessels and nerves. Edema is more likely to occur in the lower legs because there isn't much room for the muscles to swell. The muscles in the lower legs are covered by fibrous tissue called fascia. Fascia is not very elastic.

## Open Injuries

An open soft tissue injury is an injury where the surface of the skin or the mucous membrane is broken, exposing underlying, deeper tissue. This type of injury requires a thorough assessment and appropriate BLS care.

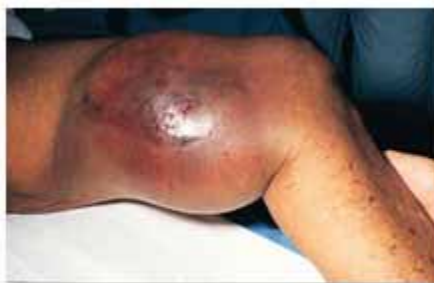**Contusion** is the medical term for a bruise that results from a blunt force applied to the soft tissues of the body. It may involve the skin, muscles or other soft structures.



**Contusion**

If blood leaks out into the soft tissues in a contusion it may lead to discoloration and the skin may turn black or blue. The term for such discoloration under the skin is *ecchymosis*.

A **hematoma** is a collection of blood under the skin. It can occur in any soft tissue such as skin or muscle. A hematoma is caused when blood leaks from an injured vessel.



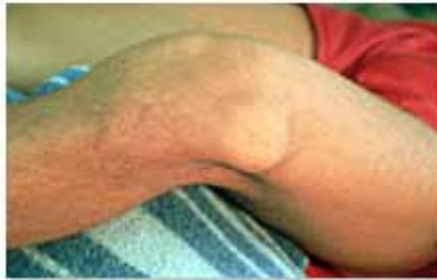**Hematoma**

Injury to soft tissues from blunt force leads to swelling and edema. **Edema** is the medical term for swelling as a result of fluid in the skin or muscle. If the swelling becomes great enough it may put pressure on blood vessels and nerves. Edema is more likely to occur in the lower legs because there isn't much room for the muscles to swell. The muscles in the lower legs are covered by fibrous tissue called *fascia*. Fascia is not very elastic.

A **sprain** is a joint injury involving damage to supporting ligaments and partial or temporary dislocation of bone ends. Pain and swelling are often seen with this type of

injury. A **strain**, on the other hand, involves stretching or tearing of a muscle. It is also called a *muscle pull*.

A **dislocation** occurs when the bone ends that form a joint become separated. Dislocations occur in moving joints such as shoulders, elbows, fingers, toes, knees, ankles and hip joints. The shoulder is the most commonly dislocated major joint.



**Knee dislocation**

Dislocated joints are very painful (especially large joints) and a patient generally will hold the extremity in the most comfortable position possible. Do not attempt to move the joint unless there is a good reason to do so, for example, the lack of distal pulse or sensation. A patient with a dislocated joint will often have an associated fracture of the nearby bone.

**Crush injuries** are associated with significant mechanisms of injury. If a force is great enough, soft tissue (muscles, vessels, skin) can be crushed leading to extensive tissue damage and subsequent swelling and pain. Crush injuries in the lower extremities and forearm can lead to *compartment syndrome* that generally takes a few hours to develop.

## Burns

Burns can be caused by heat, electricity and chemicals. Burns of the soft tissue can be life-threatening particularly when they involve the respiratory tract or occur over extensive areas of the skin. Burns of the skin can lead to shock and sepsis which both occur hours after the trauma occurs. Always be alert to possible airway involvement.

Even if a patient has no signs of external burns, there can be inhalation injuries. These can pose a serious problem. Signs of burns involving the respiratory tract include:

- Burns of the face, nose, mouth or chest
- Singed eyebrows, lashes or nasal hair
- Abnormal breath sounds such as stridor, wheezes or rhonchi
- Inadequate chest expansion
- Sooty sputum
- Respiratory distress
- Hoarse voice or persistent cough
- History of confinement in toxic or smoky environment

## Mechanism of Injury

Mechanism of injury (MOI) is the force or forces that cause injury when applied to the human body. Forces have characteristics such as *speed*, *size* and *direction*. Your observations of the mechanism of injury are an important element in a patient's care.

There are four factors to consider when assessing a mechanism of injury.

Factor	Examples
<b>Speed</b>	<ul style="list-style-type: none"> <li>▪ Traveling approximately 50 MPH</li> <li>▪ Fall from standing</li> <li>▪ Fall from height of 15 feet</li> <li>▪ Landed on concrete floor</li> </ul>
<b>Type/Size</b>	<ul style="list-style-type: none"> <li>▪ Car versus bicycle</li> <li>▪ Automobile collision with utility pole</li> <li>▪ 12-gauge shotgun at close range</li> <li>▪ High-powered rifle (30-06)</li> <li>▪ Stabbing with a 3-inch paring knife</li> <li>▪ Air-powered nail gun (1-inch nails)</li> </ul>
<b>Direction</b>	<ul style="list-style-type: none"> <li>▪ Ankle flexed outward</li> <li>▪ Shot in the head from behind</li> <li>▪ Stabbed in side of the thorax</li> <li>▪ T-boned by station wagon</li> </ul>
<b>Other Evidence</b>	<ul style="list-style-type: none"> <li>▪ Significant damage sustained by vehicle</li> <li>▪ Intrusion into the passenger compartment</li> <li>▪ Rider was not wearing helmet</li> <li>▪ Driver was wearing safety belts</li> <li>▪ Vehicle airbags deployed</li> <li>▪ Patient states the perpetrator kicked him in the belly</li> <li>▪ Patient heard a pop on impact</li> </ul>

## Direct and Indirect Forces

A direct force is one that can cause injury at the point of impact. An indirect force can result in an injury at a point distant from the point of impact. An example of a direct force is the abdomen slamming into a steering wheel that damages the spleen. An example of an indirect force is a person falling and landing on his feet with the indirect force causing a fracture of the spine.

## Speed Kills

Traumatic injury occurs when the body is exposed to force beyond its tolerance. The energy of a moving object is called kinetic energy and is calculated as follows:

$$\text{Kinetic Energy} = \frac{\text{Mass} \times (\text{Velocity})^2}{2}$$

mass = weight  
velocity = speed

The law of kinetic energy says:

- If you double the weight of a moving object the force doubles
- If you double the speed the force quadruples

In other words, speed kills. The amount of kinetic energy or force that is delivered to a human body dictates the severity of the injury. Therefore, speed is a very important factor in evaluating mechanism of injury.

## Significant MOI

Any large force has the potential to cause serious injury. Look for evidence of high energy, penetration by a projectile or significant direct or indirect force, for example, damage to the interior of an automobile such as a bent steering wheel, broken windshield, damage to the exterior, and intrusion into the passenger compartment.

## Physical Exam

Conduct your physical exam in a systematic manner starting at the top and working your way down (neck-head-to-toe exam). Keep the chief complaint in mind as you inspect and palpate each region of the body. Look for:

- Bleeding
- Signs of shock (poor skin signs, sustained tachycardia)
- Pain and tenderness
- Limited movement
- Deformity or angulation
- Discoloration
- Swelling
- Crepitus
- Absence of distal circulation, motor function or sensation (CMS)

Also, a physical exam entails collecting and documenting baseline vital signs.

When there is a significant MOI or an obvious significant injury, immediately perform a rapid trauma survey to assess for life-threatening injuries. If time permits, you may conduct a detailed physical exam while en route.

Always consider the possibility of a head or spinal injury when the head is involved and the MOI is significant.

**Assessment vs. Diagnosis**

EMTs are not expected to make an accurate diagnosis in the field. The language that you use in your written report should reflect your impression of the injuries, based on the evidence you collect (for example, MOI, chief complaint, signs and symptoms). Here are some terms that may help you in documenting your assessment:

- Possible (e.g., possible fracture)
- Suspected (e.g., suspected dislocation)
- Potential (e.g., potential internal injury)
- Obvious (e.g., obvious angulated tib/fib fracture)

**Joint Injuries**

It is often difficult to distinguish sprains and strains from dislocations. Keep in mind that dislocations are serious injuries that require prompt attention.

Sprain/Strain	Dislocation
<ul style="list-style-type: none"> <li>▪ Relevant mechanism of injury</li> <li>▪ Point tenderness of injured joint/ligament</li> <li>▪ Swelling and ecchymosis of injured joint</li> <li>▪ Pain causing immobility</li> <li>▪ Instability</li> <li>▪ Guarding during joint motion</li> </ul>	<ul style="list-style-type: none"> <li>▪ Relevant mechanism of injury</li> <li>▪ Marked deformity of joint</li> <li>▪ Swelling</li> <li>▪ Pain aggravated by movement</li> <li>▪ Tenderness of palpation</li> <li>▪ Loss of normal joint motion</li> <li>▪ Numbness</li> <li>▪ Impaired circulation to the limb</li> </ul>

## Assessing CMS Function

Important blood vessels and nerves lie close to the bone, especially around the major joints. Assess circulation, motor and sensory function (CMS) as part of the detailed physical exam.

<b>Circulation</b>	Palpate the pulse distal to the point of injury and check skin color and/or capillary refill time.
<b>Motor</b>	Evaluate motor function by asking the patient to wiggle fingers or toes.
<b>Sensation</b>	Assess sensation and the patient's ability to sense light touch by asking the patient to identify which digit you are touching.

If you suspect that a joint is dislocated, you should assess distal nerve and vascular function by checking CMS. Repeat every 5 to 10 minutes and document the results of your assessment.

If a limb has lost circulation, motor or sensory function, attempt to reposition the dislocated joint then reassess CMS and note any changes. (*Discontinue repositioning if the patient experiences increased pain or crepitus.*)

## SAMPLE History

The SAMPLE mnemonic is a helpful tool to organize the information you collect about a patient's medical history. SAMPLE includes:

Factor	Description	Examples
<b>Symptoms</b>	<ul style="list-style-type: none"> <li>▪ Chief complaint</li> <li>▪ What happened?</li> <li>▪ Is the MOI significant?</li> </ul>	<ul style="list-style-type: none"> <li>▪ Right hip is bruised and tender</li> <li>▪ Fell 10 feet from garage roof</li> <li>▪ Landed on side</li> </ul>
<b>Allergies</b>	<ul style="list-style-type: none"> <li>▪ To medications</li> </ul>	<ul style="list-style-type: none"> <li>▪ Sulfa drugs</li> </ul>
<b>Medications</b>	<ul style="list-style-type: none"> <li>▪ Prescription, over the counter, and recreational (illicit) drugs</li> </ul>	<ul style="list-style-type: none"> <li>▪ Gliberide</li> </ul>
<b>Past medical history</b>	<ul style="list-style-type: none"> <li>▪ Medical conditions</li> </ul>	<ul style="list-style-type: none"> <li>▪ Adult-onset diabetes</li> </ul>
<b>Last oral intake</b>	<ul style="list-style-type: none"> <li>▪ Include food and drink</li> </ul>	<ul style="list-style-type: none"> <li>▪ Lunch an hour ago</li> </ul>
<b>Events leading up to the incident</b>	<ul style="list-style-type: none"> <li>▪ Include precipitating factors</li> </ul>	<ul style="list-style-type: none"> <li>▪ Remembers getting dizzy before falling</li> </ul>

## The Body's Response to Hypovolemia

The body has a predictable physiologic response when it loses a significant amount of blood. Significant blood loss, either through internal or external bleeding, causes a progression of signs that you can see in a patient.

### What Is Shock?

Shock is a life-threatening condition that develops when the circulatory system cannot deliver sufficient blood to body tissues. There are many causes including blood loss, cardiac failure, respiratory failure and spinal cord injury.

A common factor in all types of shock is inadequate perfusion of body tissues. If inadequate perfusion continues, organ failure, and eventually death, will occur.

## Care of Closed Injuries

BLS providers have various treatment options at their disposal for the care of soft tissue injuries. The following are guidelines for the care of closed soft tissue injuries.

Type of Injury	Signs/Symptoms	Treatment
Contusion Ecchymosis Hematoma Edema	<ul style="list-style-type: none"> <li>▪ Pain and bruising</li> <li>▪ Blue/black discoloration</li> <li>▪ Pain, swelling and discoloration</li> <li>▪ Pain, swelling and possible loss of function</li> </ul>	<ul style="list-style-type: none"> <li>▪ Reassure patient</li> <li>▪ Immobilize/splint if indicated</li> <li>▪ Apply ice or cold pack</li> <li>▪ Elevate</li> </ul>
Sprain Strain Dislocation	<ul style="list-style-type: none"> <li>▪ Point tenderness</li> <li>▪ Swelling and ecchymosis</li> <li>▪ Pain aggravated by movement</li> <li>▪ Instability of joint</li> <li>▪ Guarding</li> <li>▪ Tenderness on palpation</li> <li>▪ Numbness or impaired circulation</li> <li>▪ Deformity</li> </ul>	<ul style="list-style-type: none"> <li>▪ Reassure patient</li> <li>▪ Gently support the site</li> <li>▪ Check and record CMS before and after splinting</li> <li>▪ Apply ice pack</li> <li>▪ Splint and immobilize injured limb</li> <li>▪ Elevate injured limb</li> <li>▪ Arrange for transport to appropriate care center</li> </ul>
Dislocation	Same as above.	Same as above except do not elevate injured limb.

Special note: Treat hip dislocations as fractures.

## Removal of Foreign Objects

BLS providers may remove large, easily removed debris, such as glass, splinters, or gravel before bandaging. Secure large, deeply imbedded fragments or projectiles in place with a dressing and bandage.

## Decontamination of Skin

To decontaminate skin or soft tissue that has been exposed to toxic chemicals, you should remove wet chemicals (e.g., acid) by repeated flushing with water. Remove dry substances by first brushing the area and then by flushing with water.

## BLS Care for Burns

General care of burns includes:

- Scene safety
- Remove patient from the source of the burn
- Administer oxygen or provide ventilatory assistance as needed
- Remove loose debris on the burned area
- Remove wet chemicals, such as acid with repeated flushing
- Remove dry substances by first brushing then flushing
- Apply clean, sterile or clean dressings to the wounds
- Maintain body temperature
- Cover with dressings (follow local protocol)
- Determine the need for ALS

## Care of Open Injuries

The following are guidelines for the care of open soft tissue injuries:

- Consider the need for ALS
- Provide supplemental oxygen and/or ventilatory assistance, if needed
- Assess level of consciousness
- Maintain an open airway
- Ensure adequate breathing
- Control bleeding
- Maintain normal body temperature
- Monitor vital signs
- Stabilize the cervical spine, if indicated

**Do not rub or wash an open wound to remove foreign objects or material. It may cause additional bleeding. However, you may remove loose material to allow for proper dressing.**

## Dressing and Bandaging

All wounds require dressing and bandaging. Dressings help control bleeding, protect the wound from further damage and prevent further contamination. The initial dressing used to control bleeding should be sterile. Otherwise, choose a material that is as clean as possible. Cover the entire wound with the dressing. Try to extend the dressing material past the ends of the wound. Do not remove a dressing once applied. If bleeding continues, apply additional dressings over the old ones.

Bandages hold dressings in place. They should not come into direct contact with the wound. Secure the dressing with a bandage that is snug, but does not impair circulation. Wrap the dressing from distal to proximal to help reduce swelling and enhance circulation. If possible, leave the fingers and toes exposed.

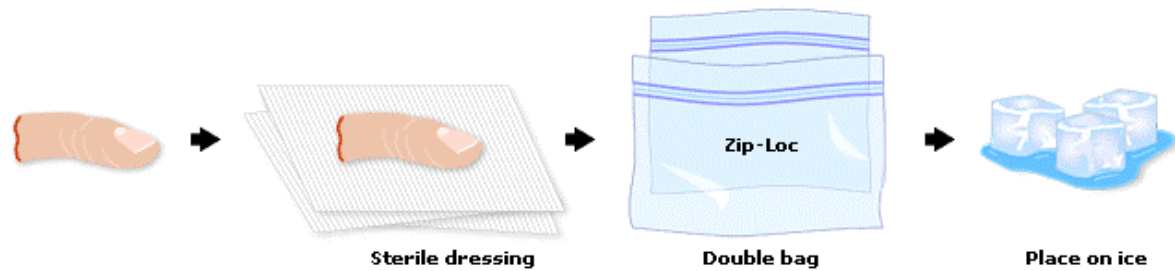
## Occlusive Dressings

Use occlusive dressings, such as plastic, to cover open wounds such as an abdominal evisceration or an open chest wound. These dressings provide an airtight seal and prevent air from entering or leaving the chest cavity. They also prevent loss of moisture in cases of open abdominal evisceration.

## Amputation Instructions

Amputations and avulsions may require control of bleeding in which case you would use direct pressure or pressure points. Use a tourniquet only as a last resort for severe life-threatening bleeding as characterized by hypotension.

Wrap amputated parts in dry, sterile dressings and place the amputated part in a watertight container. Then place the watertight container in a second container that should be placed on ice.



Emergency Care for an Amputated Part

**Do not submerge the amputated part in water or place directly on ice.** Do not use dry ice to cool a severed part; however, ice or chemical cold packs are acceptable.

Rapid transport of the patient and the severed part is critical to the success of re-implantation. If transport is delayed, consider sending the amputated part ahead to be surgically prepared.

## Summary

### Skin layers

The three layers of the skin are:

- Dermis
- Epidermis
- Subcutaneous

### Closed injuries

Types of closed soft tissue injuries include:

- Contusion
- Strain
- Hematoma and edema
- Dislocation
- Sprain
- Crush injury

### Open injuries

Types of open soft tissue injuries include:

- Laceration
- Abrasion
- Avulsion
- Amputation

### **MOI factors**

Factors to consider in assessing MOI include **speed, type/size, direction and other evidence**.

The statement that best explains kinetic energy as it relates to MOI is **SPEED KILLS**.

### **CMS status**

The steps for assessing CMS status are:

- Palpate the pulse distal to the point of injury and check skin color and/or capillary refill time (Circulation)
- Evaluate motor function by asking the patient to wiggle fingers or toes (Motor)
- Assess patient's ability to sense light touch (Sensation)

### **Care for closed injuries**

Care for a patient with a closed soft tissue injury includes:

- Reassure patient
- Immobilize/splint if indicated
- Apply ice or cold pack
- Elevate

### **Care for open injuries**

Care for a patient with an open soft tissue injury:

- Consider the need for ALS
- Provide supplemental oxygen and or ventilatory assistance, if needed
- Assess level of consciousness
- Maintain an open airway
- Ensure adequate breathing
- Control bleeding
- Maintain normal body temperature
- Monitor vital signs
- Stabilize the cervical spine, if indicated